

ORIGINAL ARTICLE

Ocular Diseases in Ancient Greek Art

Abstract

Although ancient Greek physicians studied a great number of ocular diseases in their medical texts such as glaucoma, cataract, trachoma, chalazion, trichiasis, entropion, ectropion and pterygion, in ancient Greek art there were only few examples which represent ophthalmic diseases. These examples are found especially in portraits, and the ophthalmological disease is an important feature of the portrait of a depicted person. A majority of these portraits date back to Hellenistic times except for few examples dated in prehistoric years. Although votive limbs in the form of eyes were a common dedication in the shrines of ancient healing gods as the shrines of Asklepios and Amphiaraos, one could expect the presentations of ocular diseases; all these had no pathological signs. Nevertheless, these representations of ocular diseases should be distinguished from the monstrous figures of ancient Greek mythology which remind of ophthalmological pathologies such as the Cyclops who had one eye and Argos Panoptis with more than two, because these are fantastic figures of mythology far from reality.

Keywords: Ocular Diseases, Ancient Greek Art, Portrait, Figurines, Votive Limbs

Received: 6 Dec 2015; Accepted: 27 Jan 2016; Online published: 15 May 2016
Research on History of Medicine/ 2016 May; 5(2): 57-68

Konstantinos Laios¹
Marilita M. Moschos²
George Androutsos¹

¹Medical School, University of Athens
²First Ophthalmological Clinic, Medical School, University of Athens

Correspondence:
Konstantinos Laios PhD,
Athinodorou 1, Kato Petralona, 118 53,
Athens, Attikie
konstlaios@gmail.com



Introduction

Eyes had a central role in ancient Greek culture. As the main organs which give the ability to be understood, the physical and social environment and as basic means to be expressed, the spirit and the psychic world, they had a special position in many aspects and expressions of ancient Greek though. They had a magical role in ancient Greek mythology¹. They challenged a heated philosophical debate² and ancient Greek physicians studied in depth their pathologies³. In ancient Greek art, eyes were represented in many different ways, from the most unrealistic to the most physiocratic ones⁴. But in some cases, ocular diseases were represented in realistic portraits. These portraits date back to Hellenistic times, except for few examples dated in Prehistoric years. Votive limbs in the form of eyes were produced in large numbers and were dedicated in the shrines of healing gods, but they were constructed without any sign of diseases. Some of these votive limbs were considered as representations of ocular disease, but according to our point of view this is not the case.

Materials and Methods

The earliest representation of a disease in ancient Greek art is found on a Neolithic terracotta figurine from Thessaly, which represents a boy's head with Down's syndrome (Volos, Athanasakeio Museum: M 5197)⁵ (Figure 1). The interpretation of this disease is achieved not only with the hydrocephalic head of the boy, but mainly with the presence of epicanthos (eyelid fold in the inner corner of the eye) which is unique in Neolithic figurines⁶. Very later in the Hellenistic age, we would find another example of a Hellenistic terracotta figurine again of a boy under the characteristics of the same disease representing the sign of epicanthos but this time in a more realistic way (Athens, Benaki Museum: 12615)⁷ (Figure 2).

Lagophthalmos (hare eye; unable to close eyelids even in the sleep) is another condition which appeared also in ancient Greek art. In a prehistoric Cretan tomb from the area of Platanos in Mesara dated 2500-2000 BC, an ivory figurine was found representing a man with the characteristic of facial nerve paralysis, where the lagophthalmos appears in the left eye (Herakleion, Archeological Museum: 229)⁸ (Figure 3). We could propose the hypothesis that the represented man was buried in this tomb and he probably suffered a stroke or a paresis of the facial nerve.

1. Roscher, 1884-1937.
2. Jablonski, 1930: 603-331.
3. Magnus, 1901.
4. Steinhart, 1995.
5. Chourmouziadis, 1994.
6. Marangou, 1992.
7. Richter, 1960.
8. Skoulakis, 1997.



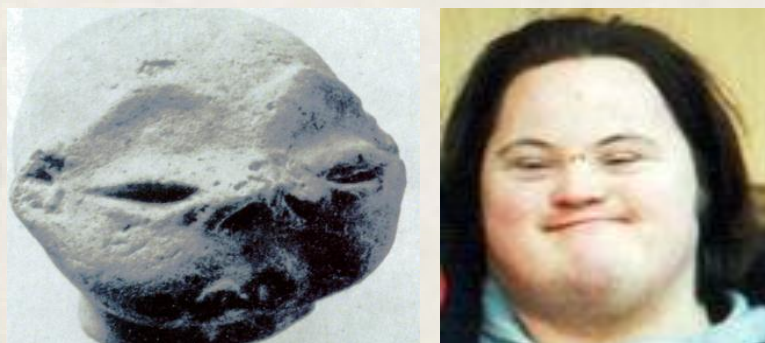

Figure 1. Neolithic terracotta figurine representing a boy's head with Down's syndrome



Figure 2. Hellenistic terracotta figurine representing a boy's head with Down's syndrome

Three other Hellenistic terracotta figurines probably represent the condition of exophthalmos. The first one dated to the 1st century BC and found in Troy, represents a woman's head with bulging eyes (Paris, Louvre: D 556)⁹ and probably a goiter as we can interpret the bulge on the throat, which is described in the official presentation of the figurine⁹ (Figure 4). In this case, the exophthalmos is obvious and probably is a symptom of Grave's disease represented in the figurine. The other two examples represent male heads with bulging eyes but the exophthalmos is lesser than in the female one. In these examples, there is not a goiter; therefore, we cannot specify the exact disease which provoked the exophthalmoses. The one figurine found in Crete (Kobenhavn, Nationalmuseet: 1436)¹⁰ depicts a beardless man and the other from Egypt (Paris, Collection Fouquet: 361)¹¹ figures an Isis priest because he wears a hat with horns between which there is a

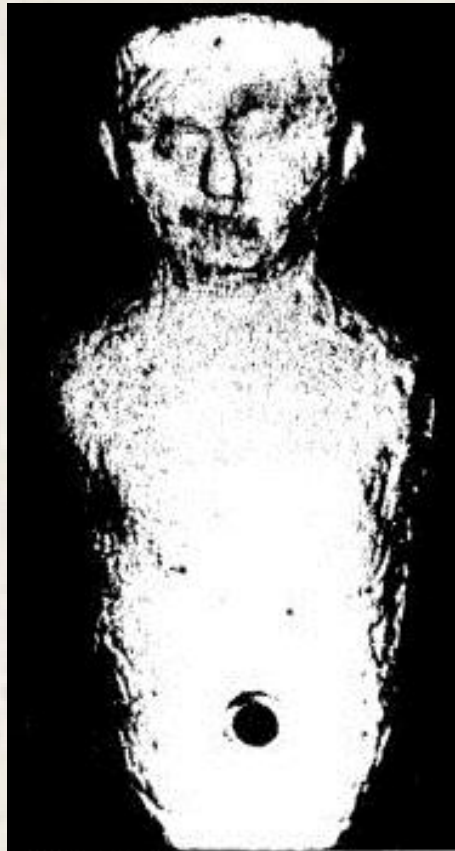9. Besques, 1971-1972.

10. Breitenstein, 1941.

11. Perdrizet P, 1921.



star (Figure 5).



12. Galeone, 1938: 331-336.

13. Künzl, 1994: 179-198.

Figure 3. Prehistoric ivory figurine representing a man with the characteristic of facial's nerve paralysis and hare eye

All the above examples represent ocular pathological conditions which come as a result of pathology. Only one Hellenistic terracotta figurine, now lost, represented a per se ophthalmological disease. This figurine was earlier in the archeological museum of Taranta¹². It represented the head of a bearded man with a huge bulge in the right eye in the region of eyebrows (Figure 6). A benign cyst could be an interpretation, but the macroscopic view indicates most likely to be depicted an orbital wall cancerous mass. It is believed it is pointless to identify this tumor with an exact type of neoplasia. This figure should be differentiated from another terracotta figurine again lost, which belonged to earlier Meyer-Steineg collection¹³. This one depicting a boy's head, undoubtedly represents retinoblastoma in the right eye. But the form of the hair and the cheek clearly indicate that it is a forged figure created in modern times, because these



characteristics do not belong to ancient Greek art as first had pointed Van Straten¹⁴.

14. Van Straten, 1981: 65-151.



Figure 4. Hellenistic terracotta figurine representing a woman with goiter and exophthalmoses



Figure 5. Hellenistic terracotta figurine representing the head of an Isis priest with an exophthalmos

In the shrines of healing gods and especially in those of Asklepios (Asklepieia) and Amphiaraos (Amphiaræia), much gold, silver, marble have been dedicated but mainly



terracotta votive limbs in the form of eyes¹⁵. The inscriptions of such dedication and the survived eye-votive limbs do not give us any information about the ocular diseases of the dedicators. Probably cataract and other refractive abnormalities were the main reasons for dedication; therefore, there were no signs of these diseases on votive limbs.



Figure 6. Hellenistic terracotta figurine representing the head of bearded man with a huge bulge in the right eye in the region of the eyebrows

Discussion

Although already from the Archaic period until Hellenistic and Roman Age¹⁶, there are a series of boxer portraits (Figure 7), having as main attributes swollen ears and fractured noses reminding of traumatism during this sport, there is not a boxer's portrait with the characteristics of a swollen eye or any other sign noting an injury in this organ. That could mean in ancient Greek box, athletes avoided hits on the eye, because it could provoke a severe damage or blindness.

Blindness has been represented in the portraits of these people with an abstract glance, while no abnormality is created in the eyes. This abstract glance is observed in the portraits of Homer¹⁷ and it is repeated in an ivory figurine (3rd quarter of 4th century BC) (Figure 8) of the portrait of Philippe II of Macedonia who lost his left eye during the battle of Methoni in 355-354 BC (Salonika, Archeological Museum: 11)¹⁸.

There was the thought that the two-eye votive limb from the Asklepieion of Corinth depict both of them ectropion¹⁹. The first one (Corinth, Archeological Museum of Ancient Corinth: V 208) is considered to represent only an ectropi-

15. Forsén, 1996.

16. Laios, 2015.

17. Grmek, 1998.

18. Andronikos, 1977: 39-72.

19. Roebuck, 1951.



on (Figure 9), while the second one (Corinth, Archeological Museum of Ancient Corinth: V208a) to represent also a burned eyeball (Figure 10)²⁰. We believe these votive limbs lack realism, allowing us to believe that the inclination of the eyelids and the incising in order to be presented iris and pupil, which give the impression of an eye burn, are probably a result of poor workmanship. The great number of eye votive limbs in the Athenian Asklepieion, as we are informed of an inscription (IG II2 1532-1537), was the reason to express the idea that this Asklepieion was specialized in ophthalmic diseases¹⁴. But we do not have an overall picture of the dedications in this shrine to reach this conclusion, while other inscriptions inform us about many other votive limbs dedicated in the same place²¹.

20. Chaviara - Karahaliou, 1990: 135-139.

21. Aleshire, 1989.



Figure 7. Hellenistic terracotta figurine representing a boxer with swollen ear (Athens, National Archeological Museum: 5764)

Finally, the monstrous figures of ancient Greek mythology with one eye like Cyclops (Figure 11) and more than one like Argos Panoptis (Greek: the one who can see everything) (Figure 12) who had up to 100 eyes on his body, should not be related to similar monster births, because mythology is an area which does not accept any pathological phenomenon,



while every mythological monster represents fantastic creatures which are related to fear and the evil²².

22. Graf, 1993.



Figure 8. Hellenistic ivory portrait of Philippe II of Macedonia



Figure 9. Eye votive limb from the Asklepieion of Corinth (Corinth, Archeological Museum of Ancient Corinth: V208)





23. Laios, 2015.

Figure 10. Eye votive limb from the Asklepieion of Corinth (Corinth, Archeological Museum of Ancient Corinth: V208a)




Figure 11. Attic Black Figure Oinochoe dated ca. 510 - 490 BC representing the blindness of Cyclops Polyphemos by Odysseus' comrades (Paris, Louvre: F342)

Conclusion

In conclusion, the ocular diseases depicted in ancient Greek art are very few in number despite the fact that numerous ancient Greek artistic creatures represent various diseases²³. All the representations of ocular diseases, with only one exception, concern ocular symptoms of other pathologies. This probably derives from the fact that the majority of ophthalmic diseases are related to refractive anomalies in which eyeball is preserved in its normal form, while other ocular disease which are observed by the change of the colors of this organ, did not give the opportunity to the ancient artists to produce long lasting creation, because painted colors faint. Finally, it must be noted that monstrous figures of ancient Greek mythology under the characteristics of ocular pathologies should



not be confused for representations of these pathologies, because these unearthly figurines fulfill the aims of mythology which is far from any pathological phenomenon.




Figure 12. Attic Red Figure Amphora dated ca. 490 BC representing the killing of Argos Panoptis by Hermes (Museum für Kunst und Gewerbe, Hamburg: 1966.34)

Acknowledgments

Konstantinos Laios states the scanning copyright for all figures.

References

- Aleshire SB. *The Athenian Asklepieion: the People, Their Dedications, and the Inventories*. Amsterdam: JC Gieben. 1989.
- Andronikos M. [*Vergina Oi Vasilikoi Tafoi Ste Megali Toumba*]. AAA. 1977; 39-72. [in Greek].
- Besques S. [*Musée National Du Louvre. Catalogue Raisonné Des Figurines et Reliefs En Terre – Cuite Grecs, Etrusques et Romains. Epoques Hellénistique et Romaine, Grèce et Asie Mineure*]. Paris: Éditions Des Musées Nationaux; 1972, p. 3-8. [in French].
- Breitenstein N. *Catalogue of Terracottas Cypriot, Greek, Etrusco-Italian and Roman in the Danish Museum*. Copenhagen: E Munksgaard. 1941.
- Chaviara Karahaliou S. Eye Votives in the Asklepieion of Ancient Corinth. *Docophth*. 1990; 74(1) 135-139.
- Chourmouziadis G. [*Ta Neolithika Eidolia*]. Thessaloniki: Vantias Editions. 1994. [in Greek].
- Forsén B. [*Griechische Gliederweihungen: Eine Untersuchung Zu Ihrer Typologie Und Ihrer Religions Und Sozialgeschichtlichen Bedeutung*]. Helsinki: Suomen Ateenan-instituutin säätiö, 1996. [in German].
- Galeone A. [Stati Patologici Nnell Arte Greca]. *Atti Mem Accad Stor Arte Sanit*. 1938; 4: 331-336. [in Italian].



- Graf F. *Greek Mythology: an Introduction*. Baltimore: Johns Hopkins University Press. 1993.
- Grmek MD. Gourevitch D. [*Les Maladies Dans l'art Antique*]. Paris: Fayard; 1998. 518. p. [in French].
- Jablonski W. [Die Theorie Des Sehens Im Griechischen Altertum Bis Auf Aristoteles]. *Sudhoffs Arch*. 1930; 306-31. [in German].
- Künzl E. Zimmerman S. [Notizen Zu Den Votiven Der Sammlung Meyer-Steineg in Jena Teill II]. *JbRGZM* 1994; 41(1): 179-198. [in German].
- Laios K. [*Oi Asthenies Kai e Eikonographia Tous Kata Ten Archeotita*]. Athens: Saripoleion Bibliotheke. 2015. [in Greek].
- Magnus H. [*Die Augenheilkunde Der Alten*]. Breslau: Kern. 1901. [in German].
- Marangou C. [*Ειδώλια, Figurines et Miniatures Du Néolithique Récent et Du Bronze Ancien en Grèce*]. France: Oxford Tempus Reparatum. 1992. [in French].
- Perdrizet P. [*Les Terres Cuites Grecques D'Égypte de La Collection Fouquet*]. Paris: Berger Levrault; 1921. 180. P. [in French].
- Richter GMA. *Greek portraits III: How were likenesses transmitted in ancient times? Small portraits and near-portraits in terracotta, Greek and Roman*. Bruxelles-Berchem: Latomus, 1960.
- Roebuck C. *The Asklepieion and Lerna*. Princeton: American School of Classical Studies at Athens; 1951. 182 p.
- Roscher WH. [*Ausführliches Lexikon Der Griechischen und Römischen Mythologie*]. Leipzig, B.G.: Teubner, 1884. [in German].
- Skoulakis C. [*Melete Kranion Kai Eidolon Pou Apeikonizoun Ten Kefali Kai Ton Trachilo Apo te Minoiki Periodo*]. Dissertation. University of Crete, 1997. [in Greek].
- Steinhart M. [*Das Motiv Des Auges in Der Griechischen Bildkunst*]. Mainz am Rhein: Philipp Von Zabern, 1995. [in German].
- Van Straten FT. Gifts for the Gods. In: Versnel HS. (Ed.). *Faith, Hope and Worship: Aspects of Religious Mentality in the Ancient World*. Leiden: Brill; 1981: 65-151.





Haft-Seen also spelled as Haft Sīn (Persian: هفت‌سین, the seven seen's) is a tabletop (sofreh) arrangement of seven symbolic items traditionally displayed at Nowruz, the Persian new year. The haft-seen table includes seven items all starting with the letter Seen (letter) (fa) (س) in the Persian alphabet.

The Haft-Seen items are:

Sabzeh (سبزه) – wheat, barley, mung bean or lentil sprouts growing in a dish - symbolizing rebirth

Samanu (سمنو) – sweet pudding made from wheat germ – symbolizing affluence

Senjed (سنجد) – dried oleaster Wild Olive fruit – symbolizing love

Seer (سیر) – garlic – symbolizing the medicine and health

Seeb (سیب) – apple – symbolizing beauty

Somāq (سماق) – sumac fruit – symbolizing (the color of) sunrise

Serkeh (سرکه) – vinegar – symbolizing old-age and patience

WWW.RHM.IR